

Case Report

Laparoscopic Gastric Bypass for Morbid Obesity in a Patient with Situs Inversus

A.C. WITGROVE, M.D., F.A.C.S. and G.W. CLARK, M.D.

ABSTRACT

The purpose of this article is to discuss the operative challenges posed by the advanced laparoscopic approach to a patient with situs inversus. The patient is a morbidly obese woman who has multiple co-morbidities related to her weight and who presented for bariatric surgery. A laparoscopic gastric by-pass was successfully performed. Situs inversus totalis is not a contraindication for laparoscopic surgery.

INTRODUCTION

WE DEVELOPED THE LAPAROSCOPIC GASTRIC BYPASS ROUX EN Y, as a surgical treatment for morbid obesity, and published our work in 1994.¹ Our operative technique and results have been documented.² To date, we have performed over 250 such cases successfully. We have presented data to reflect our improved operating room times, decreased surgical morbidity, and resolution of the associated co-morbid diseases.³ Despite this experience, the anatomic reversal seen with situs inversus created some uncomfortable challenges in the operating room.

CASE REPORT

The patient is a 38-year-old woman. At presentation she was 168 cm tall and weighed 135 kg with a body mass index of 47.8 kg/m². She suffered from the co-morbidities listed in Table 1. Her medications included Prilosec and Proventil on a daily basis.

We use the criteria established by the National Institutes of Health Consensus Panel⁴ when considering patients as candidates for bariatric surgery. This patient clearly fell within those guidelines: body mass index of more than 40, multiple dietary failures, and co-morbid conditions associated with her obesity.

During the preoperative evaluation, the patient volunteered the fact that her heart was on the wrong side as evidenced by chest x-ray. She was not sure if her intra-abdominal organs were reversed. Routine chest x-ray, electrocardiogram, and blood chemistries were obtained before her scheduled operation, but no contrasted bowel studies were performed. We assumed that the patient's intra-abdominal organs were all normal, just reversed.

WITTGROVE AND CLARK

TABLE 1. PREOPERATIVE AND 5-MONTH POSTOPERATIVE, CO-MORBIDITIES

<i>Co-morbidity</i>	<i>Preoperative</i>	<i>Postoperative</i>
Gastroesophageal reflux	Severe	Resolved
Asthma	Severe	Resolved
Arthritis (weight bearing)	Marked	Minor
Stress incontinence	Pad worn	No pad
Hypercholesterolemia	265 mg/dl	189 mg/dl
Hypertriglyceridemia	327 mg/dl	245 mg/dl

Surgery was started with the primary surgeon standing on the right side of the operating table, as per our routine. The insufflation needle was placed in the right subcostal space rather than the left to avoid injury to the liver. After insufflation and insertion of the midline trocar, we were able to assess the upper abdomen directly with the laparoscope. This confirmed the gall bladder to be on the left and the greater curvature of the stomach to be toward the right. The primary and assistant surgeon changed sides of the table at this point.

The operation involves transection of the stomach with a 15-cc proximal pouch while the distal stomach is defunctionalized. The small bowel is divided about 20 cm distal to the ligament of Treitz. An enteroenterostomy is created, and the roux en y limb is brought up to the proximal stomach, through a retrogastric approach, for the gastroenterostomy (Fig. 1). All anastomoses are intraperitoneal and are performed with Ethicon Endo-Surgery stapling devices. Full description of the operative procedure is outlined in our previous publications.¹⁻³

After fully dividing the stomach, the small bowel was addressed. The ligament of Treitz was normally placed, in a reversed position. We also traced the ascending, transverse, and descending portions of the colon to ensure that our orientation was correct.

The operation took 300 min (as compared to our average time of 159 min for the next 12 cases, three of which included cholecystectomies). The patient was discharged in 2 days. At 3 and 5 months, she weighed 105 kg and 95 kg, respectively (corresponding to a loss of 40% and 55% of her excess body weight). She has no signs or symptoms of gastroesophageal reflux disease or associated reactive airway disease. Her urinary incontinence and arthritic symptoms are improved. She now needs no medication (Table 1).

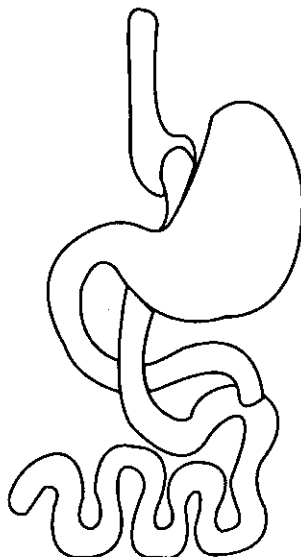


FIG. 1. Proximal gastric bypass.

DISCUSSION

Several articles have discussed the incidence of situs inversus and the issue of performing laparoscopic cholecystectomies on these patients.⁵⁻⁸ Few if any cases have been reported dealing with advanced laparoscopic procedures.

Our team had performed over 85 laparoscopic gastric bypasses prior to this case, and we have extensive experience in routine laparoscopic work. Despite this experience, there were several aspects of the operation that proved challenging.

We found it was easier for the primary surgeon to work from the left side of the table rather than the usual right side. The primary surgeon also assists and therefore is accustomed to manipulating instruments from the left side of the operating table. The assistant does not perform laparoscopic surgery as the primary surgeon and therefore does not operate laparoscopically from the right-hand side of the operating table. When one changes sides, the opposite hand is responsible for the tasks performed. Being ambidextrous is helpful in this situation. We also found it unsettling to use foot control devices with the opposite foot. Our team uses foot controls for the electrocautery unit as well as for our robotic camera holder. Both are controlled by the primary surgeon.

Despite the disorienting nature of operating on a mirror-image individual, it was done safely and efficiently, we believe, because the operating team had sufficient experience on which to draw. We found that when we were performing acts that were particularly awkward or disorienting, it helped to remind each other of the patient's anatomical differences. These auditory prompts helped to override the automatic movements, which in this case were often counterproductive.

REFERENCES

1. Wittgrove AC, Clark GW, Tremblay LJ: Laparoscopic gastric bypass, roux en-y: Preliminary report of five cases. *Obes Surg* 1994;4:353-357.
2. Wittgrove AC, Clark GW: Laparoscopic gastric bypass, roux en-Y: Experience of 27 cases, with 3-18 months follow-up. *Obes Surg* 1996;6:54-57.
3. Wittgrove AC, Clark GW: Laparoscopic gastric bypass, roux-en-Y: Technique and results in 75 patients with 3-30 months follow-up. *Obes Surg* 1996;6:500-504.
4. Gastrointestinal Surgery for Severe Obesity: Consensus development conference panel, National Institutes of Health. *Ann Int Med* 1991;115:956-961.
5. McDermott JP, Caushaj PF: ERCP and laparoscopic cholecystectomy for cholangitis in a 66-year-old male with situs inversus. *Surg Endosc* 1994;8:1227-1229.
6. Gosh P, Tekant Y, Shang NS, et al: Laparoscopic cholecystectomy in a patient with empyema of the gallbladder and situs inversus. *Endoscopy* 1992;9:799-800.
7. Champos L, Sipes E: Laparoscopic cholecystectomy in a 39 year-old female with situs inversus. *J Laparoendosc Surg* 1991;2:123-126.
8. Takei H, Maxwell J, Clancy T: Laparoscopic cholecystectomy in situs inversus totalis. *J Laparoendosc Surg* 1992;4:171-176.

Address reprint requests to:
Alan C. Wittgrove
6719 Alvarado Rd.
Suite 308
San Diego, CA 92120